

# Total Hip Joint Revision

Kyon and BioMedtrix  
Noncemented

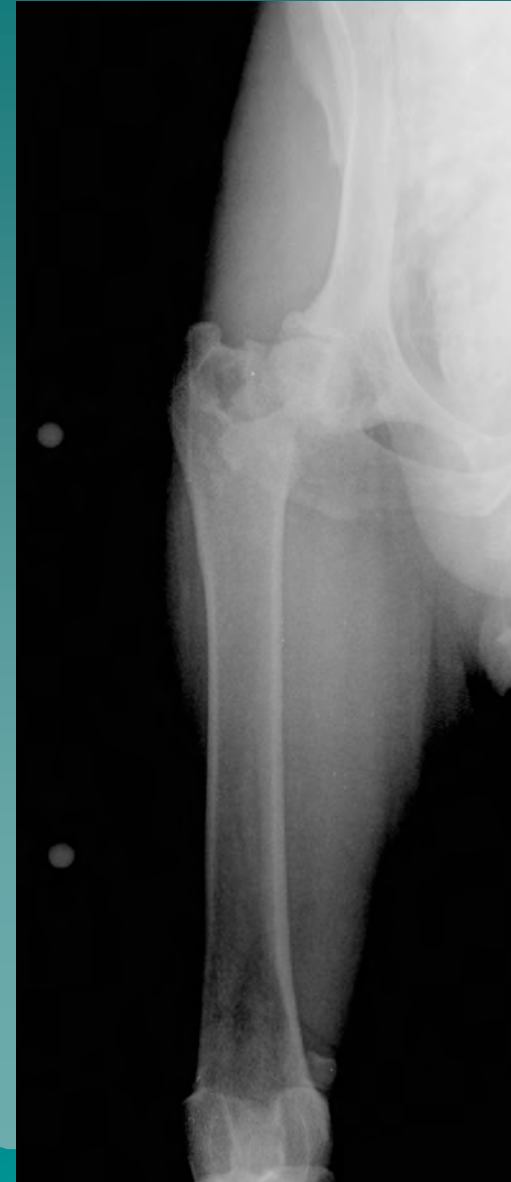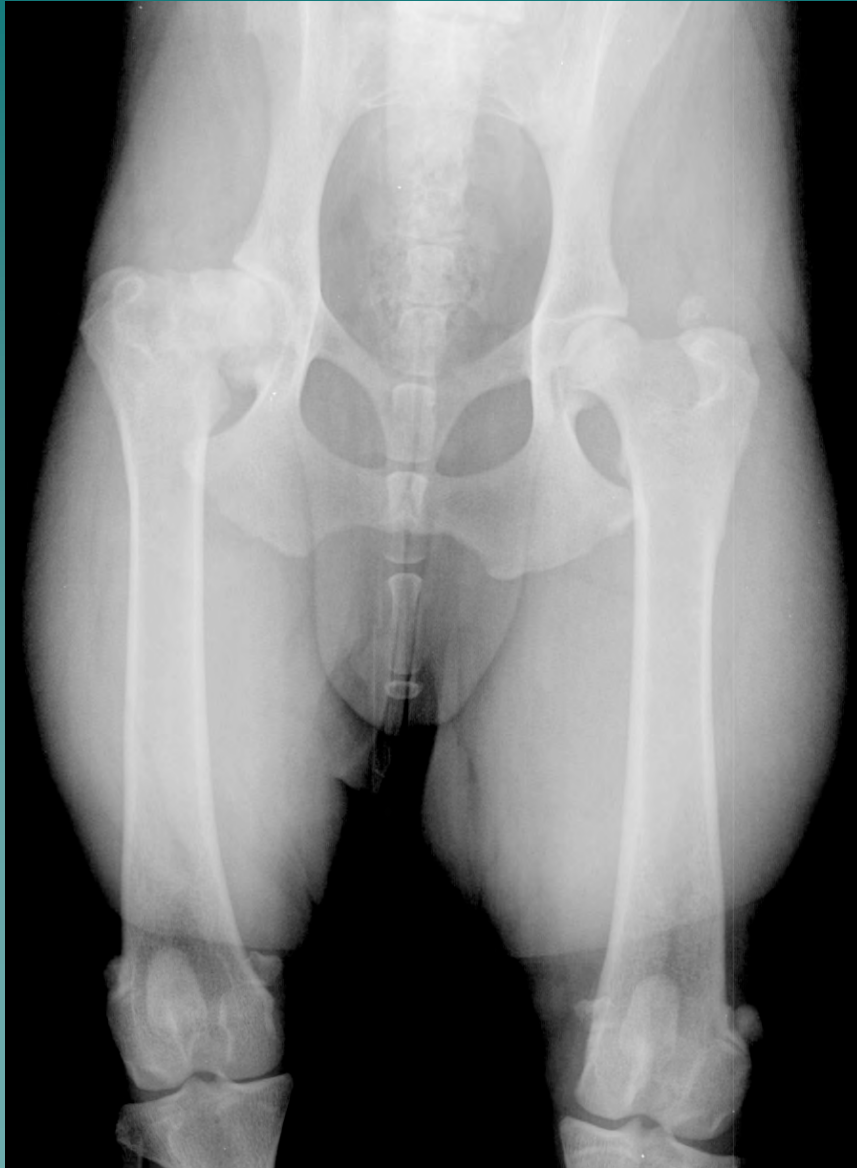Hybrid

Jim Boulay, DVM, MS,  
DACVS

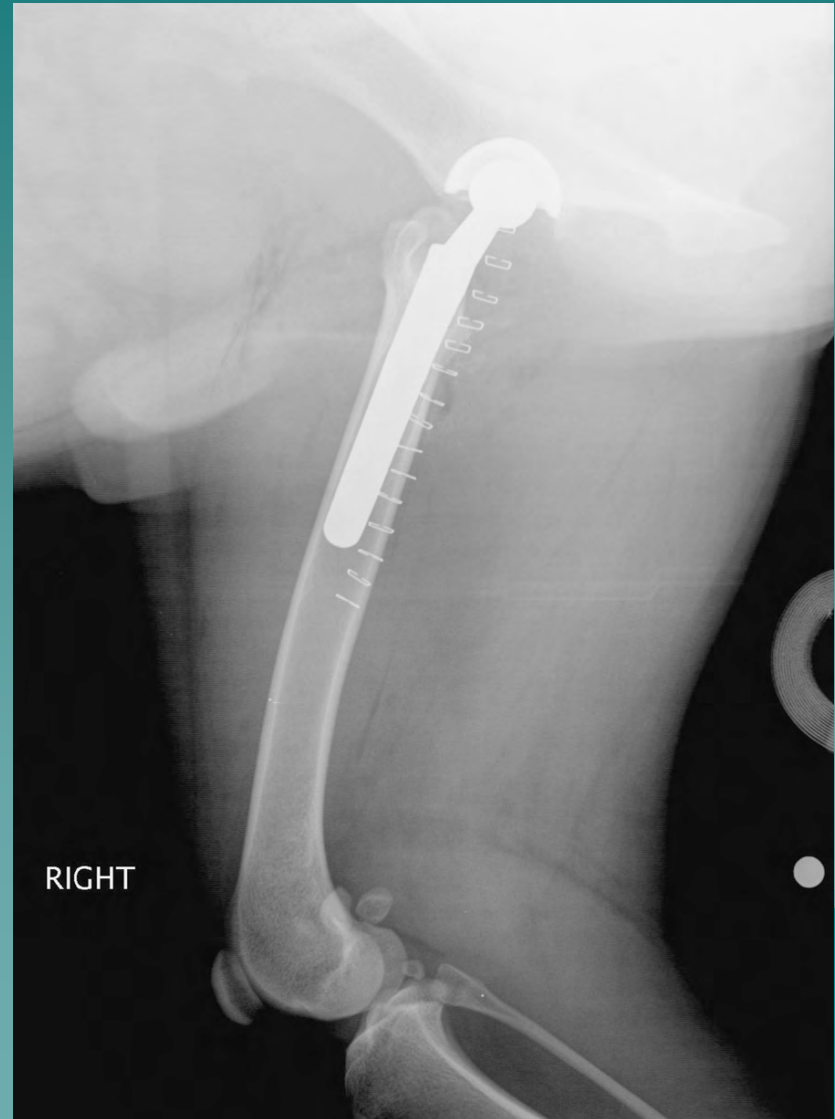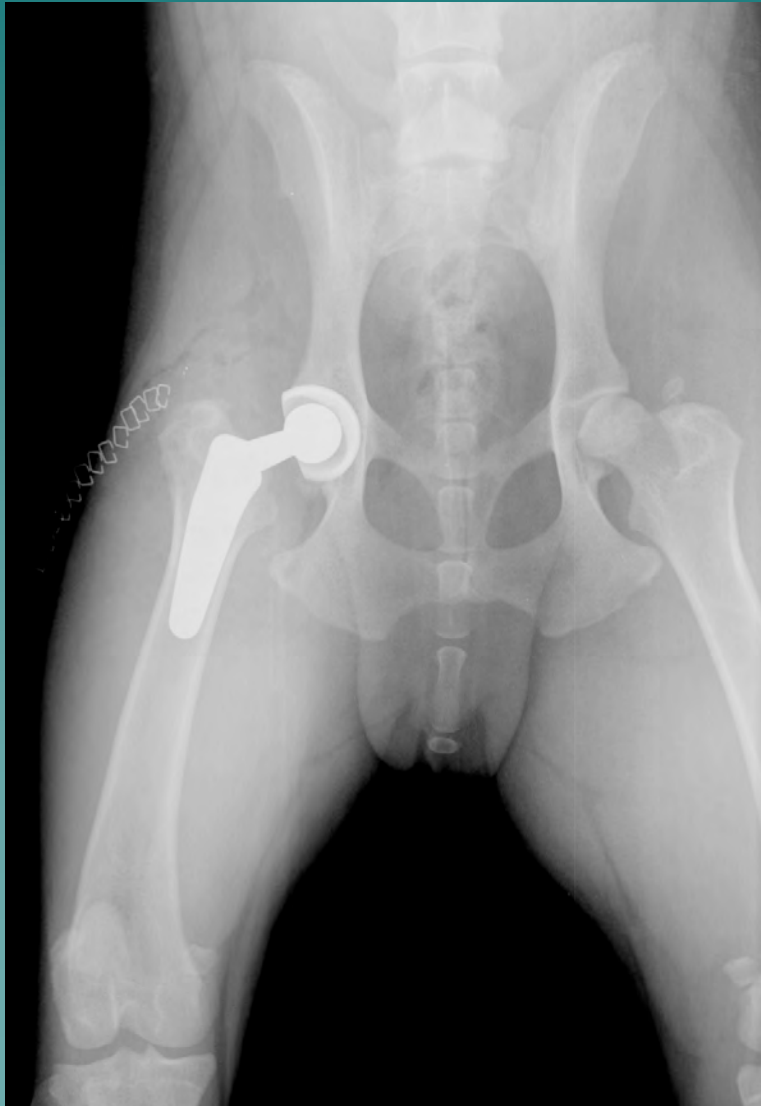
# Signalment and History

- ◆ 2 year old Rottweiler
- ◆ Trauma resulted in right front angular limb deformity and right coxofemoral arthropathy
- ◆ Angular limb correction 13 months of age, circular fixator
- ◆ Total hip replacement at 21 months of age

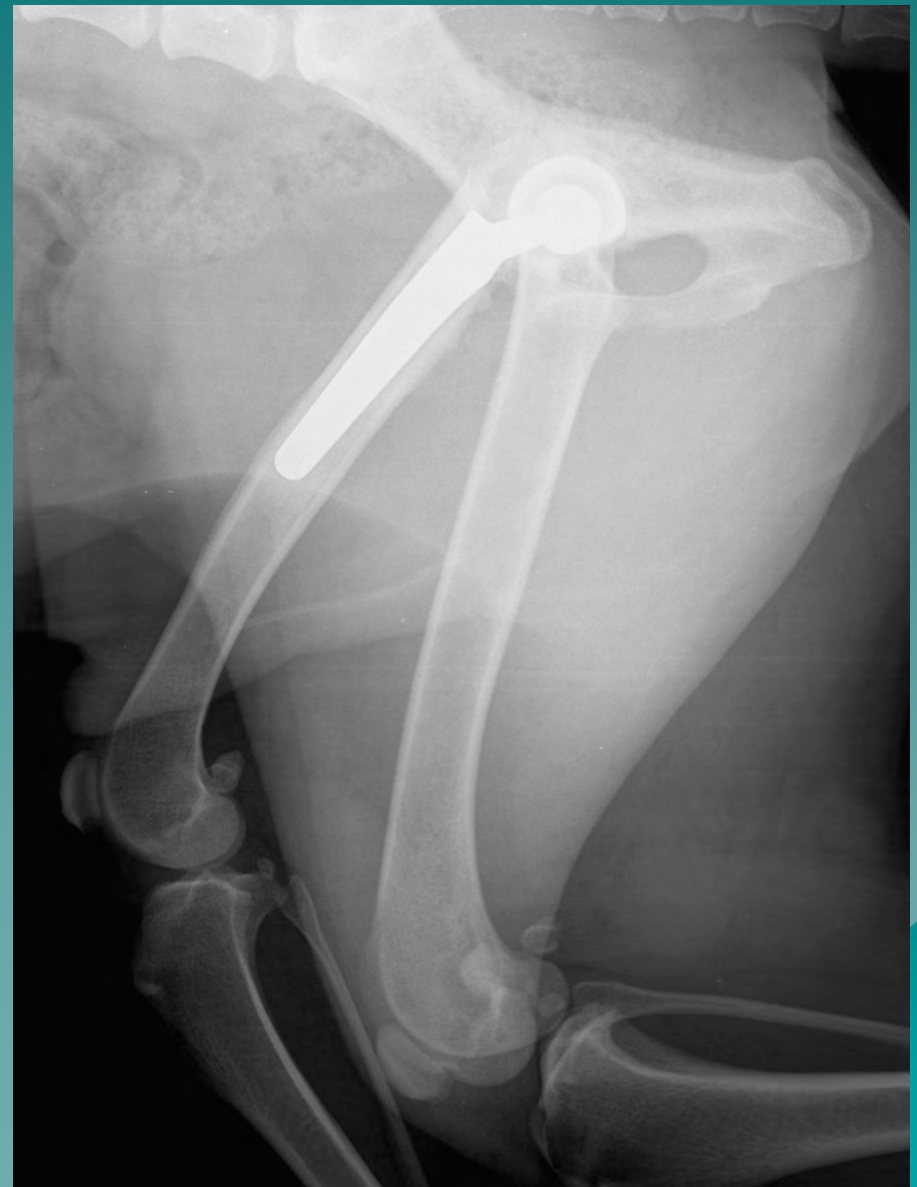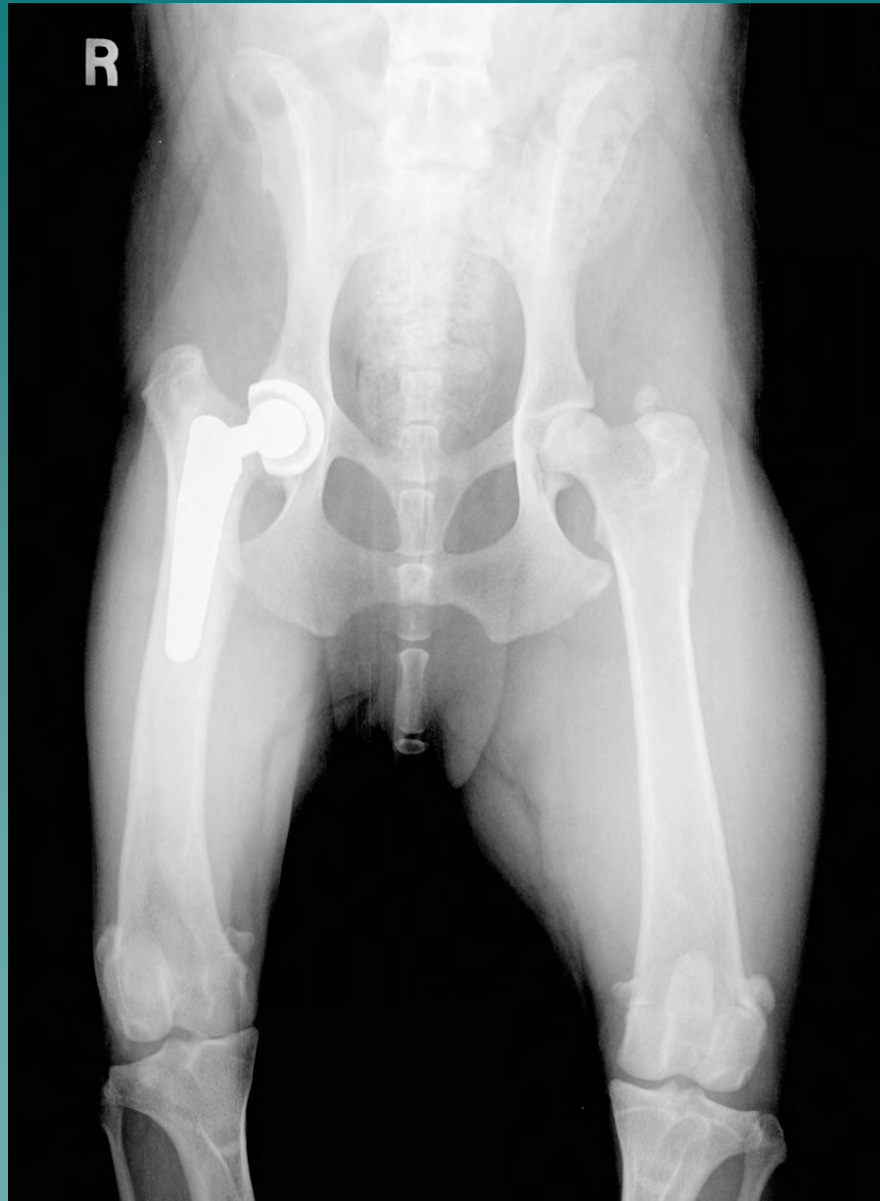# Preoperative Hip Radiographs



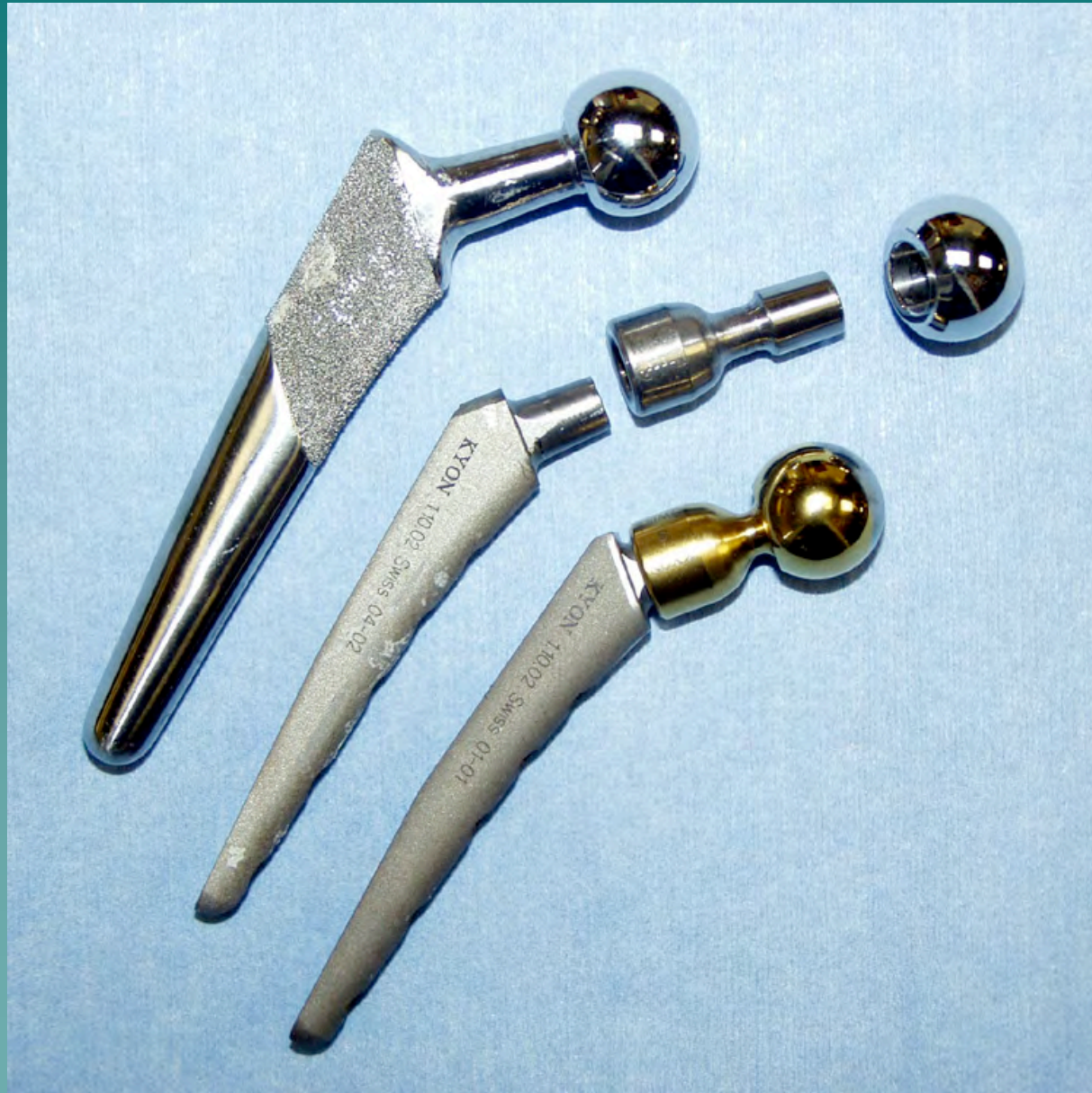# Postoperative Hip Radiographs BFX System



# Hip Radiographs - 6 Weeks PO

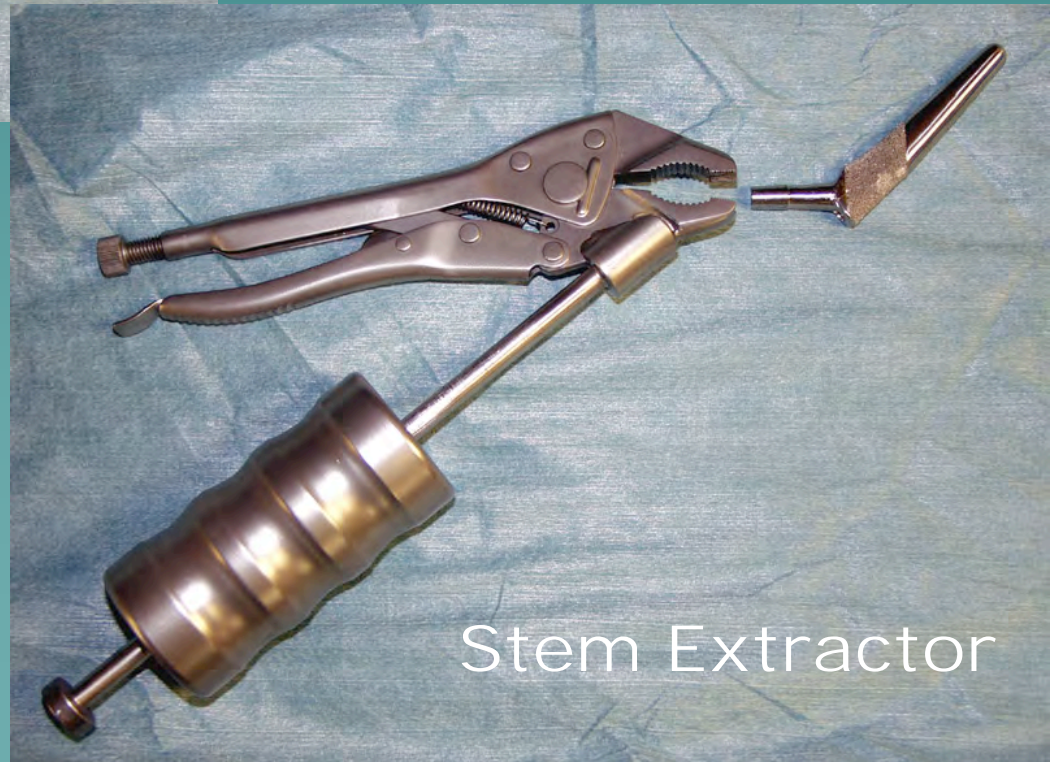


# Hip Revision - Implants



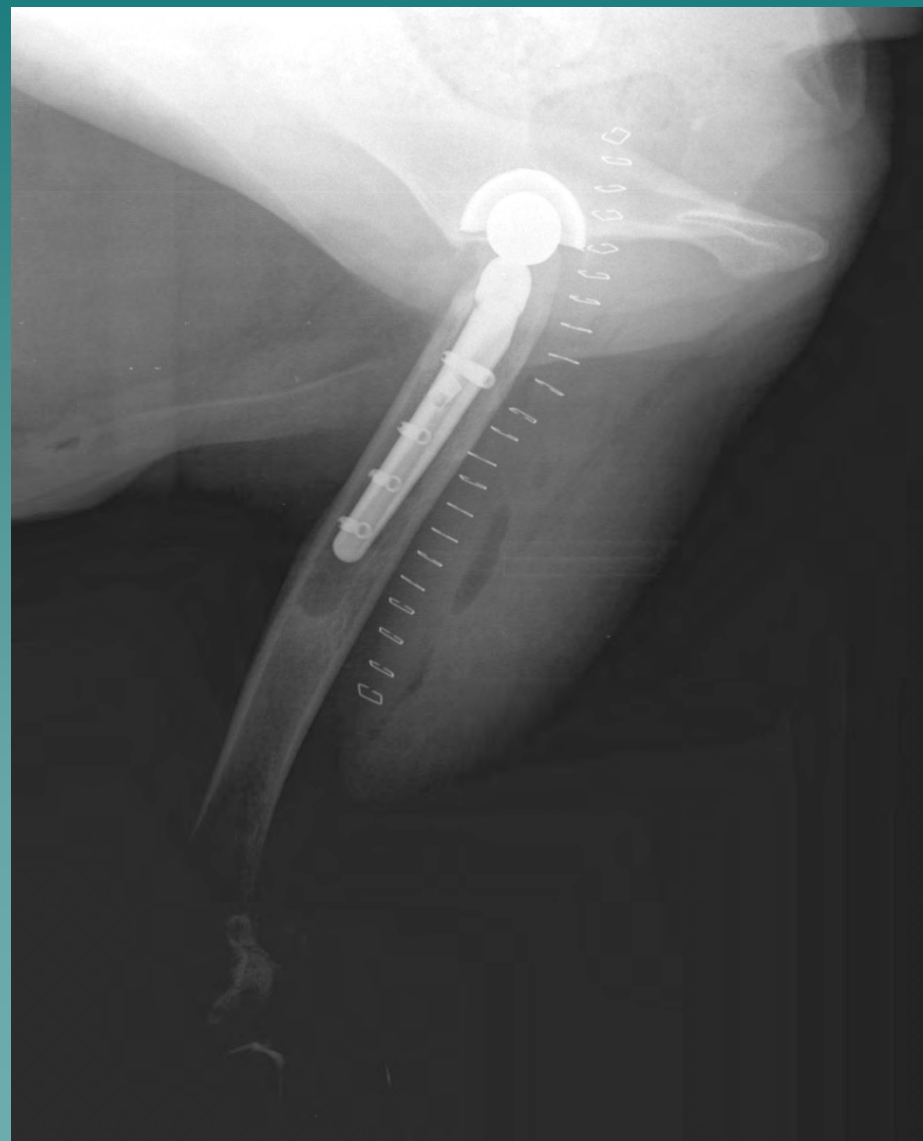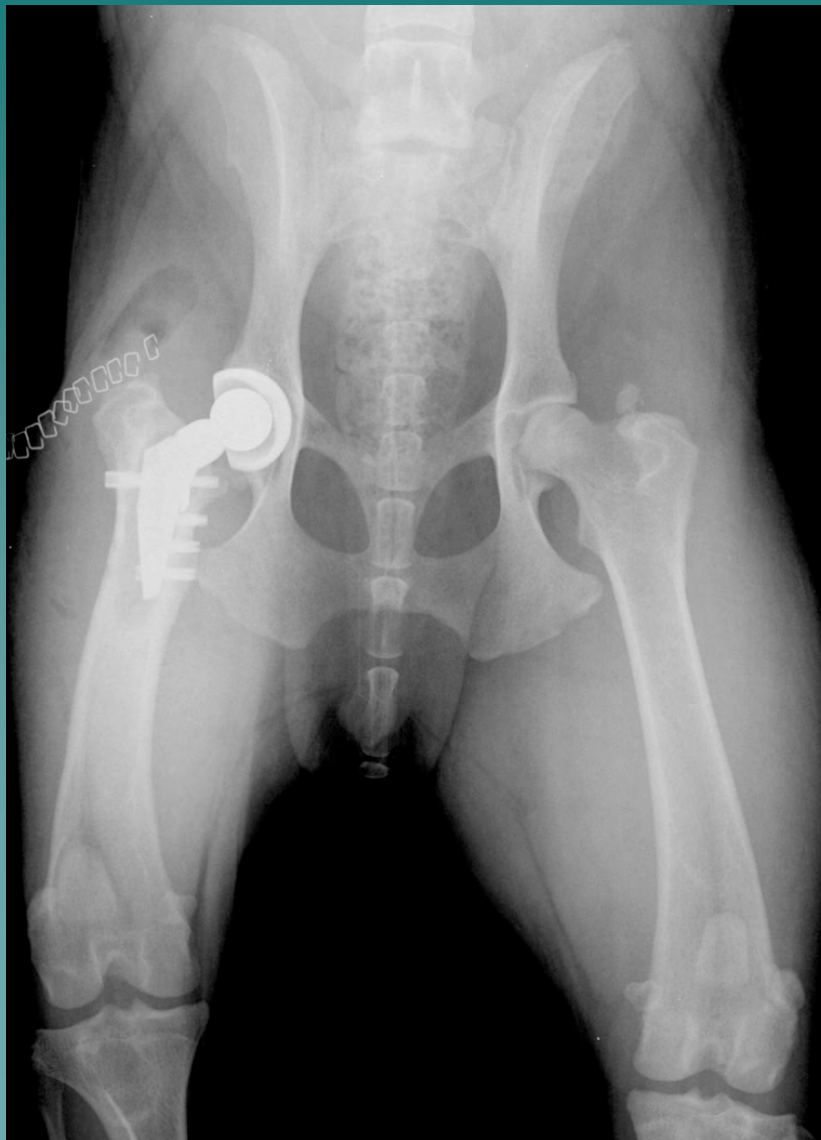
# BFX Hip Revision - Special Instrumentation

Head Extractor

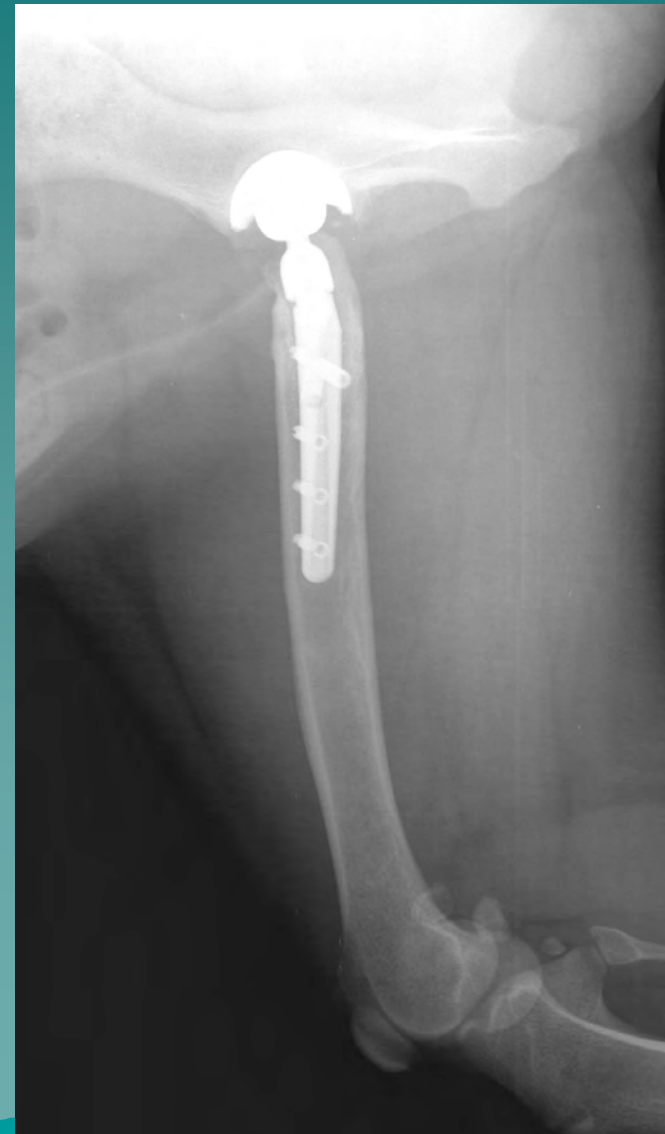
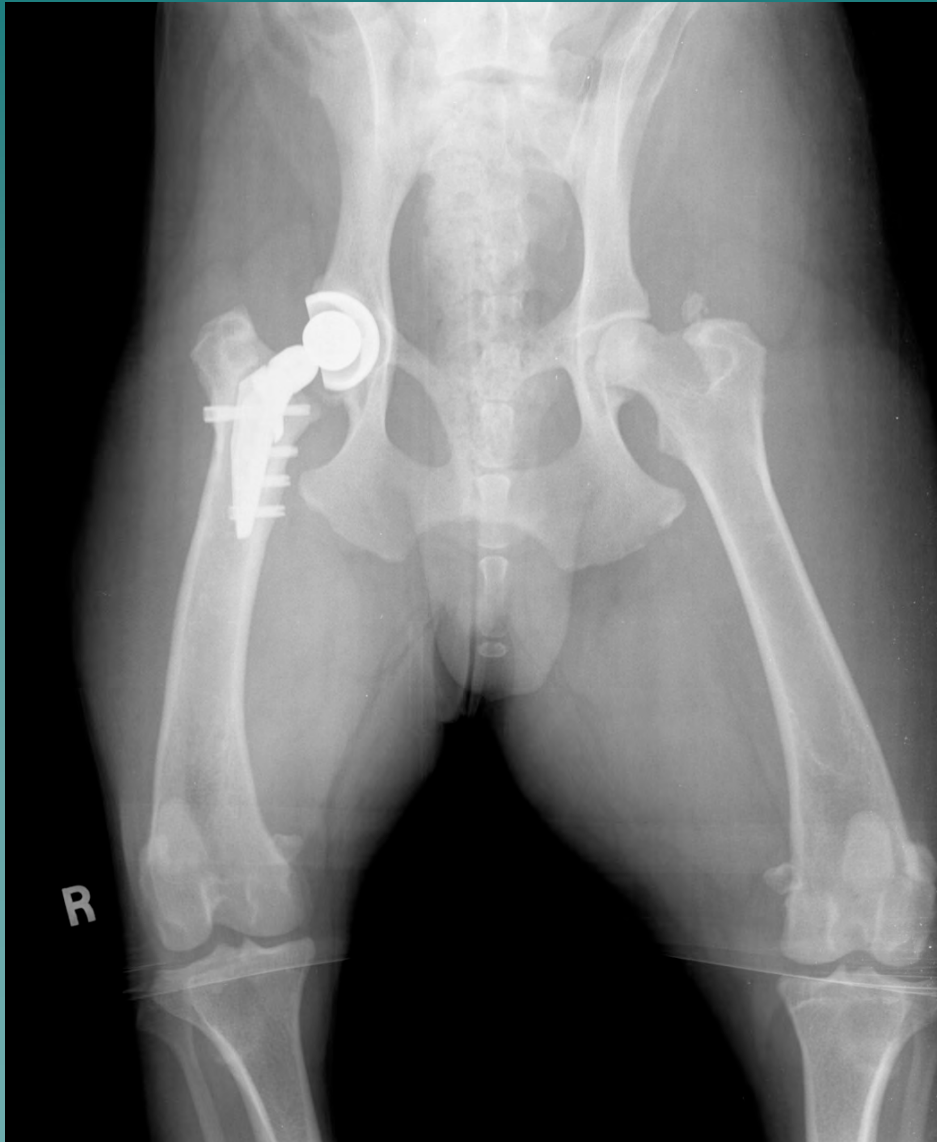
Stem Extractor

# Hip Radiographs PO BFX Hip Revision Kyon Hybrid



# Hip Radiographs 6 Weeks PO Hip Revision



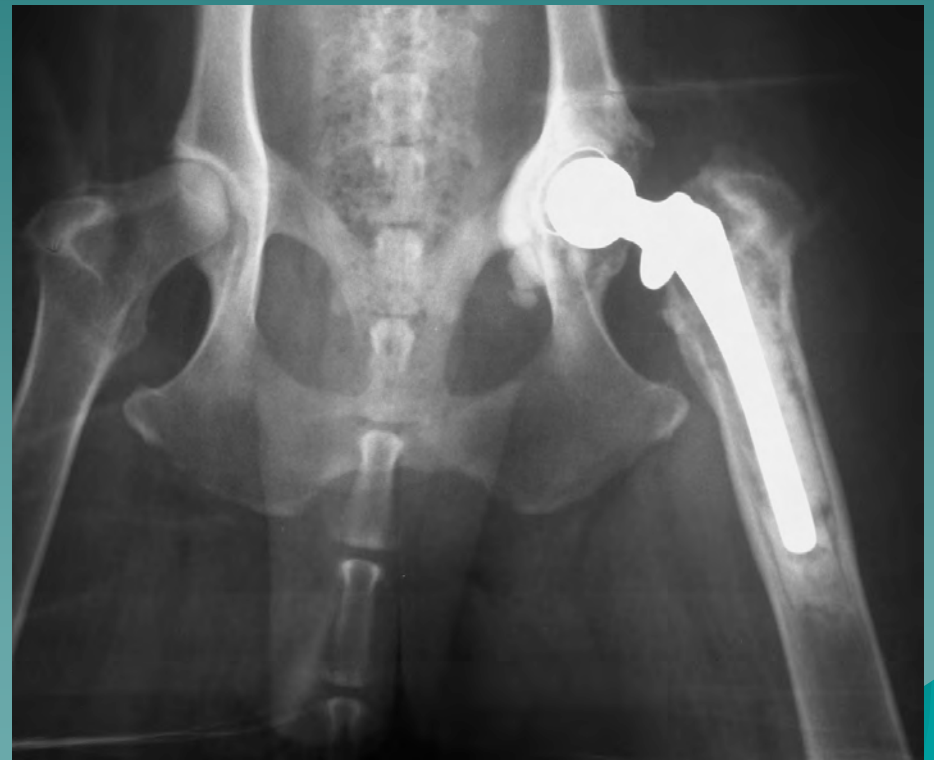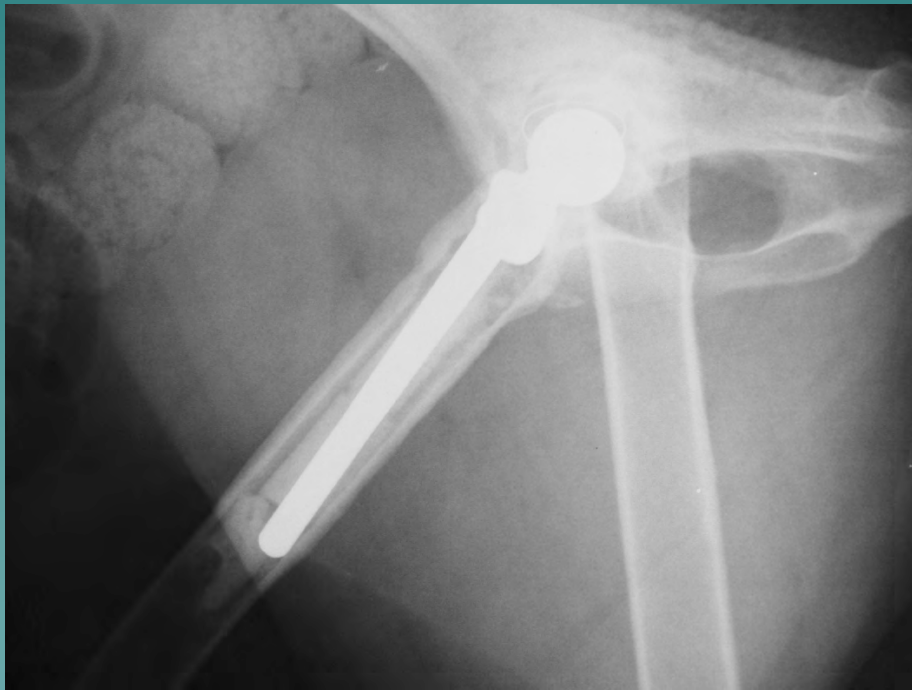
# Total Hip Joint Revision

Kyon and BioMedtrix  
Cemented  
Hybrid

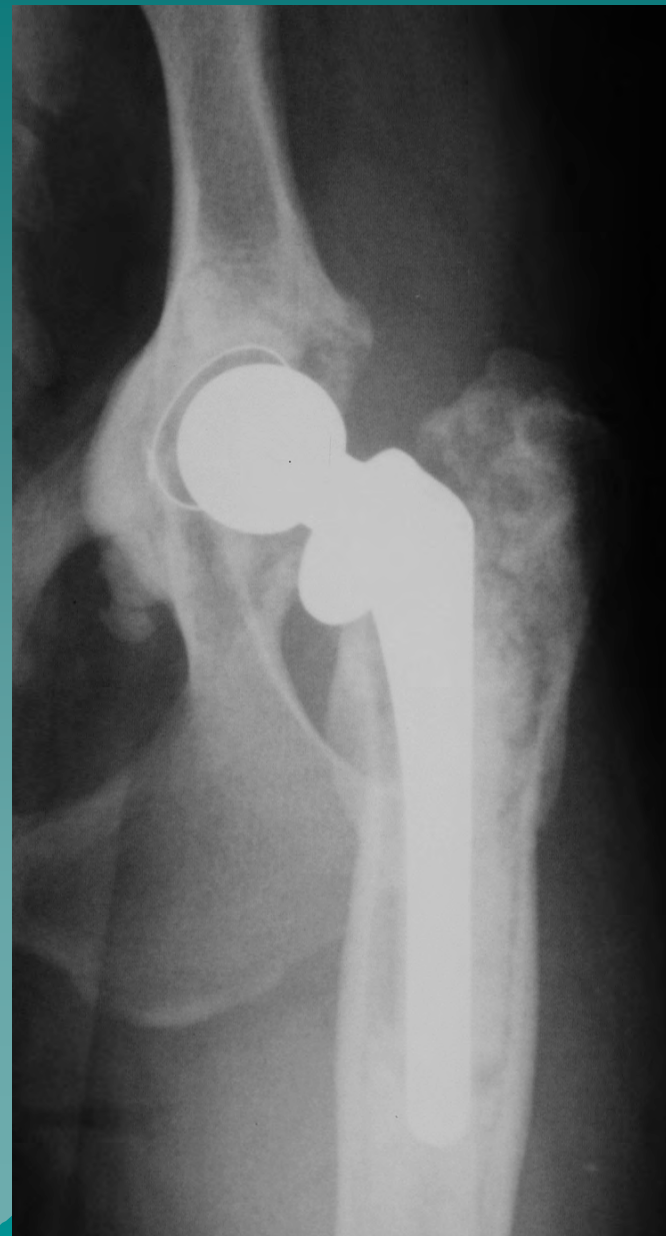
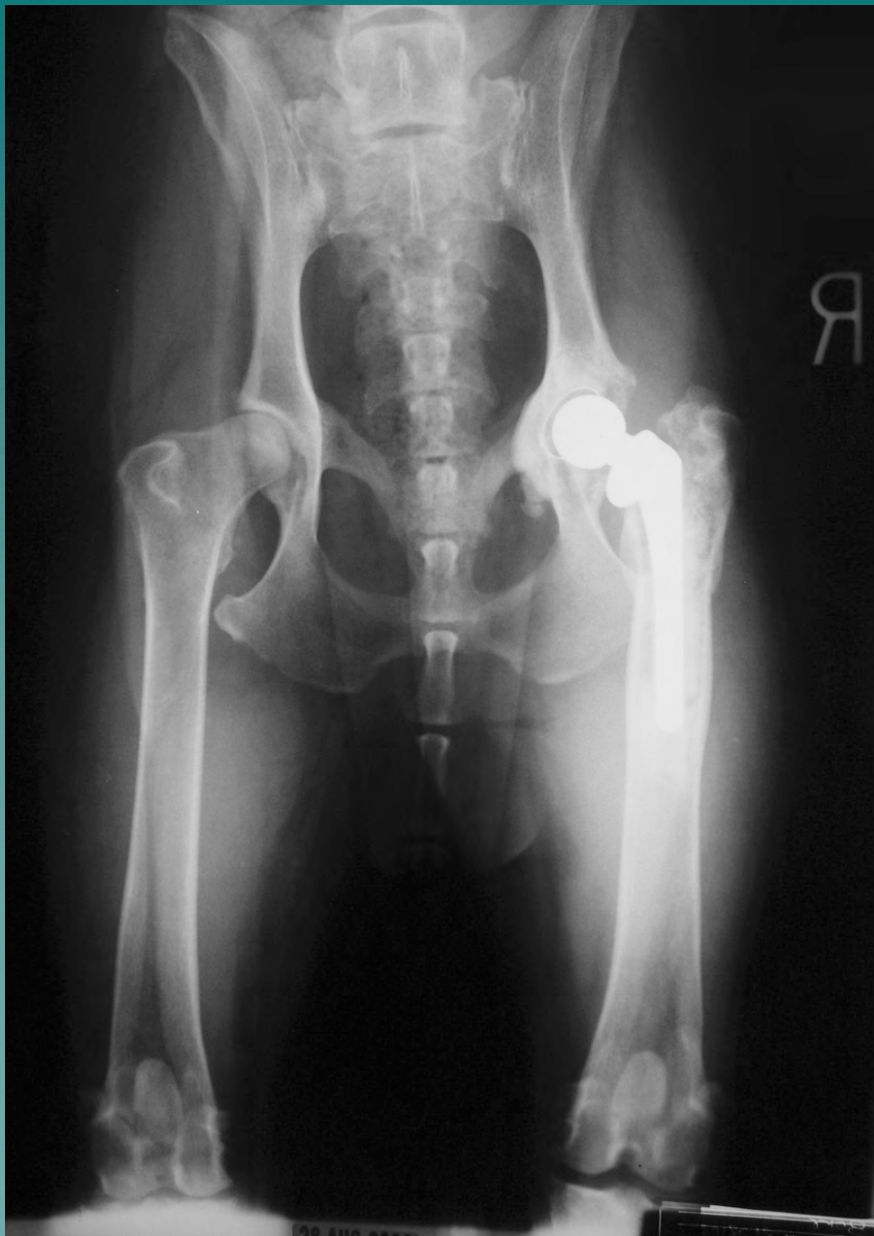# Signalment and History

- ◆ 6 year old SF Labrador-Rottweiler Mix
- ◆ R THR (CFX) at 4 years of age
- ◆ Presented for L CrCL rupture
  - Loose CFX stem noted on radiographs
- ◆ L TPLO performed
- ◆ 1 year later: R hip revision
  - CFX to Kyon hybrid

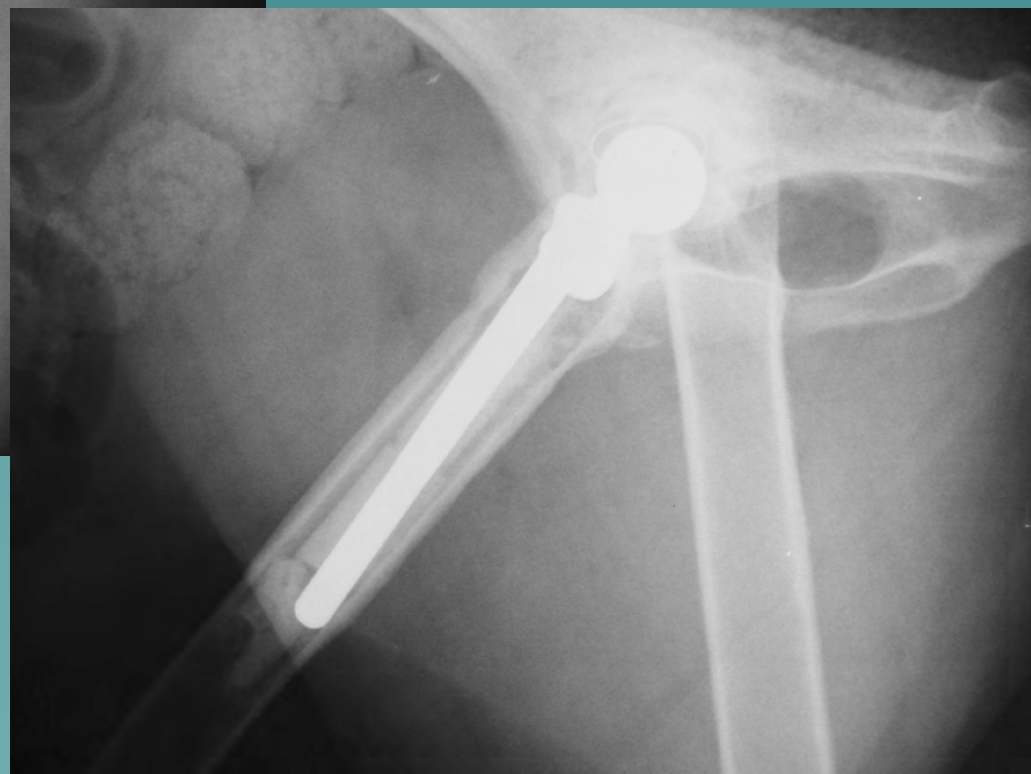
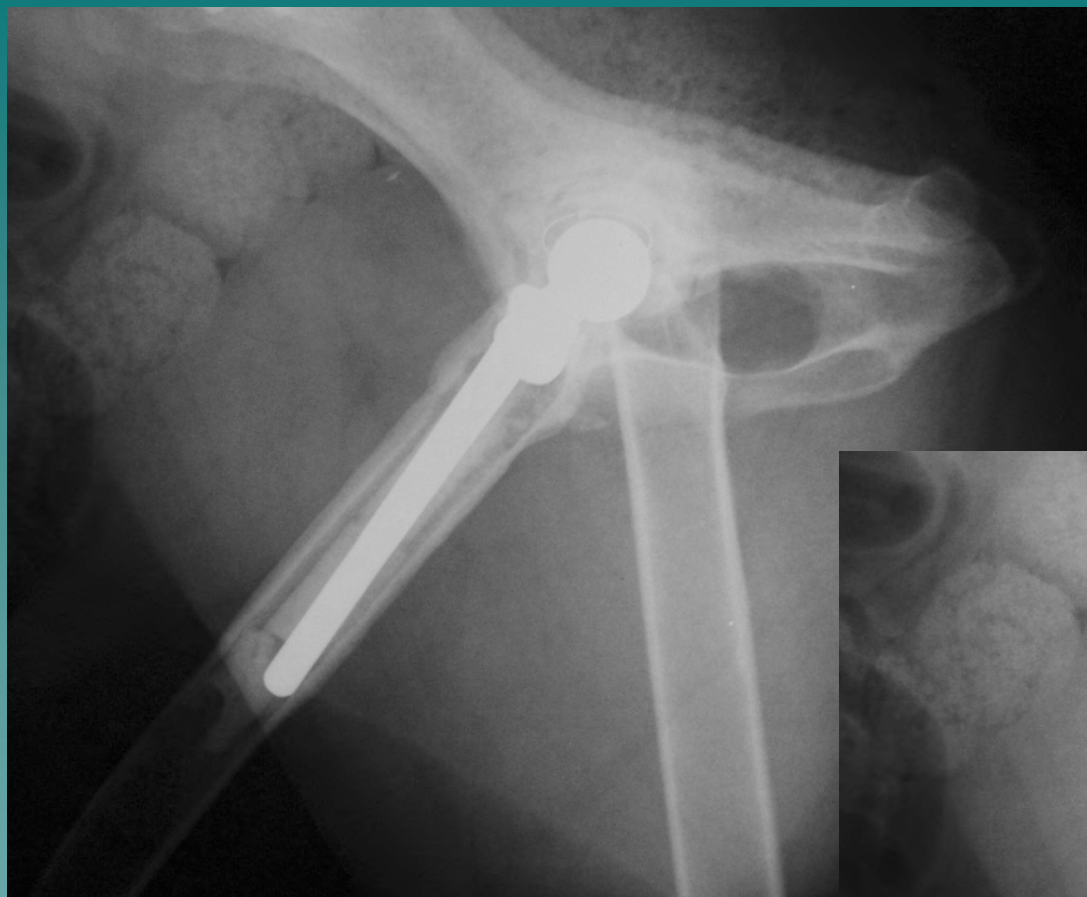# Loose BioMedtrix CFX Stem



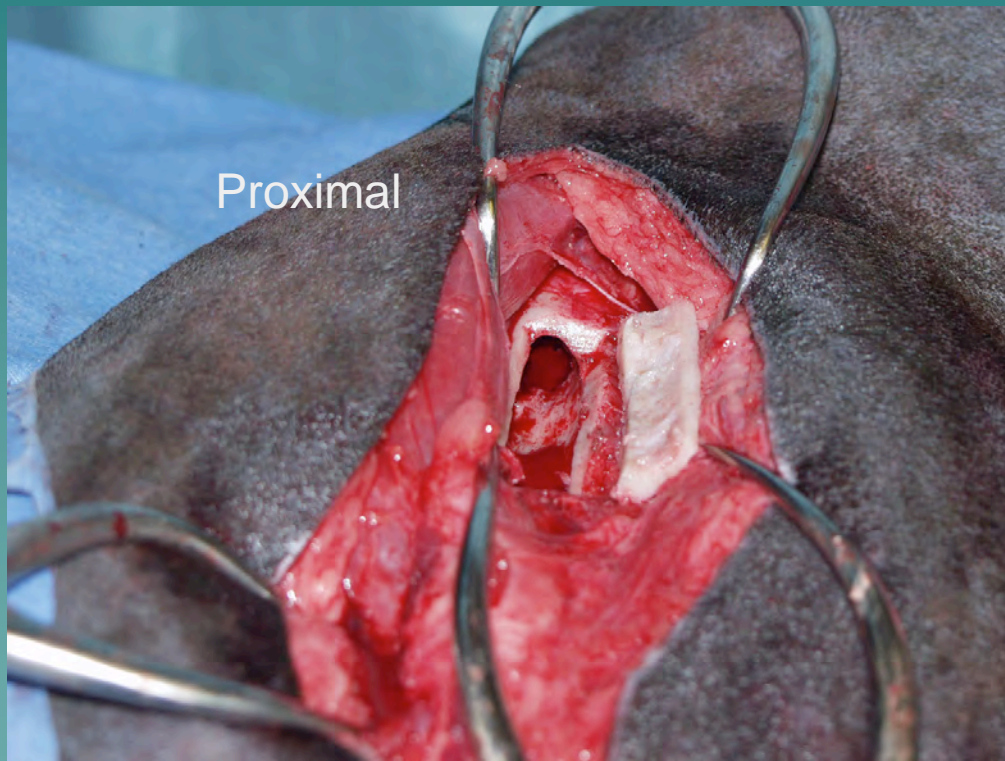
# BioMedtrix CFX Hip Loose Implant



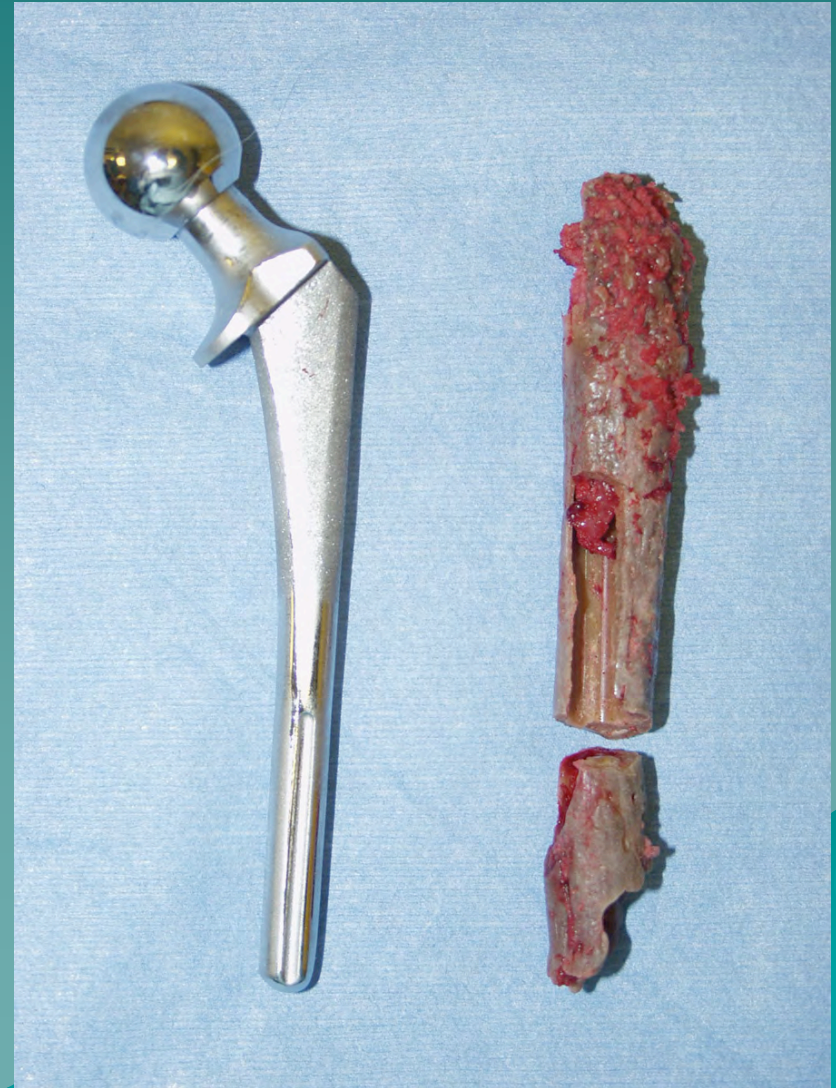# BioMedtrix CFX Hip Loose Implant



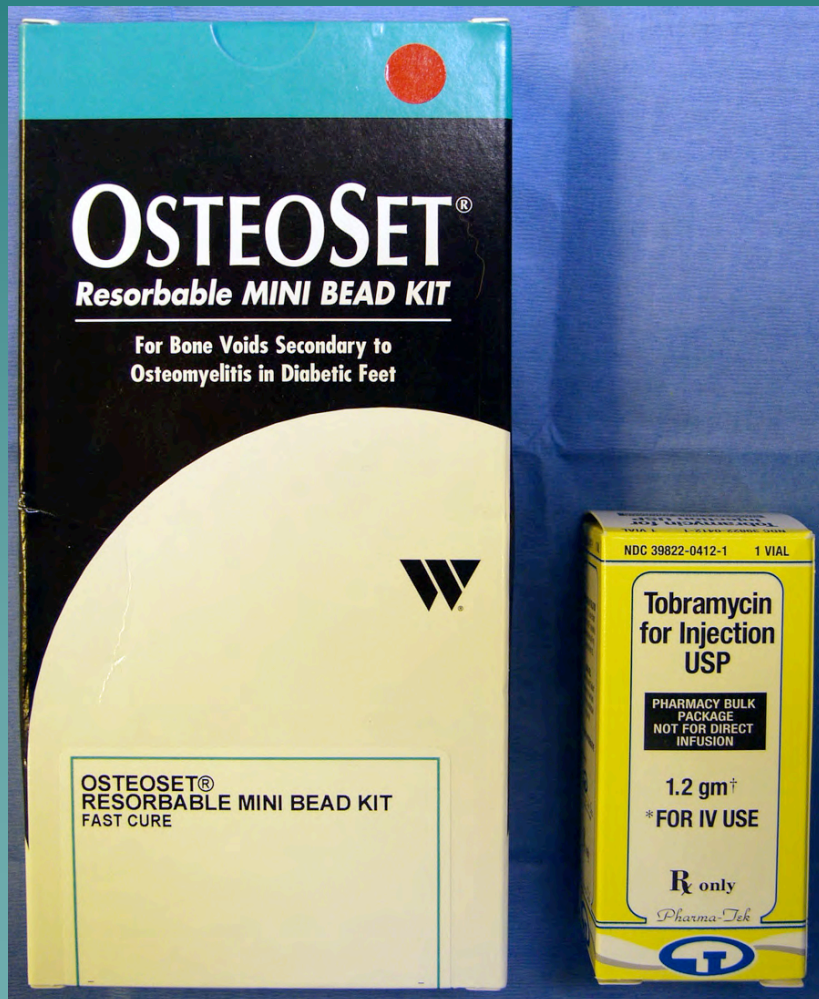
# Femoral window to explant stem and cement



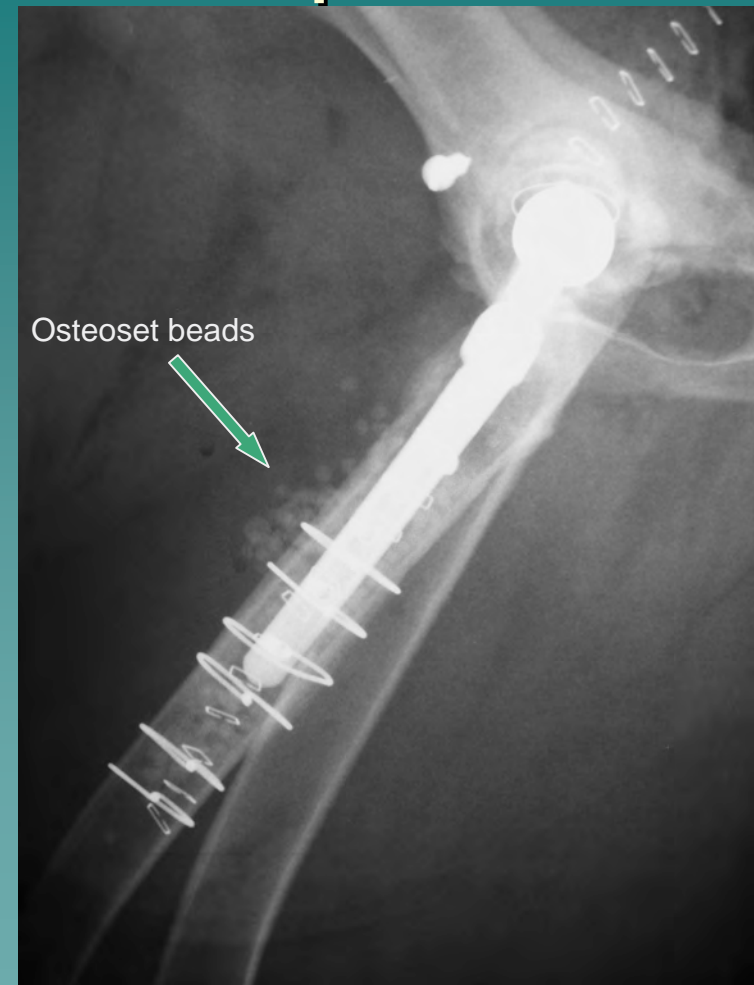
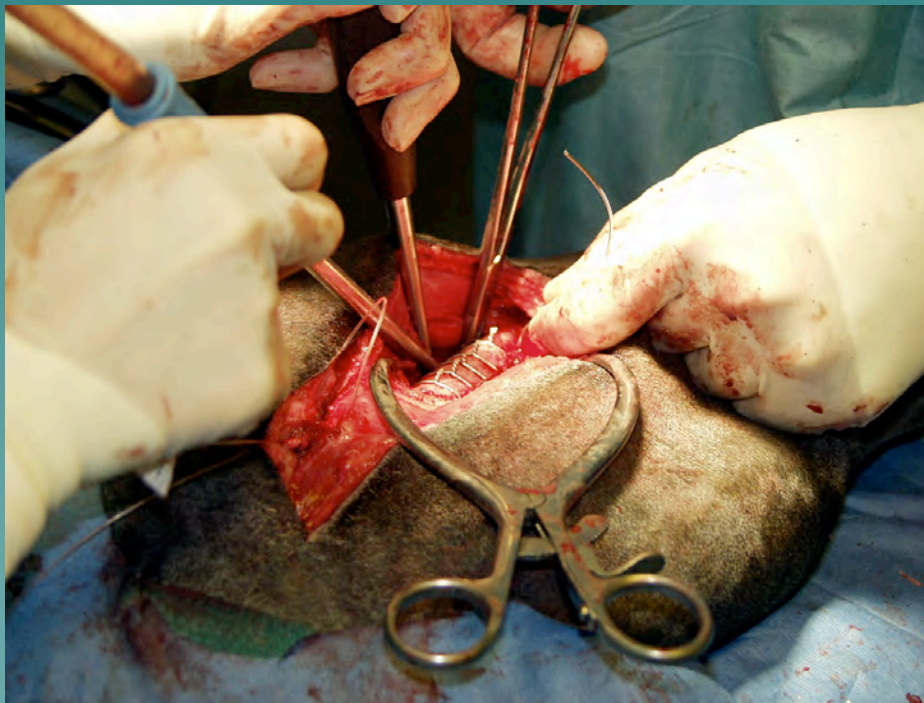
Distal



# Osteoset Beads with Tobramycin packed into femoral window around new Kyon stem



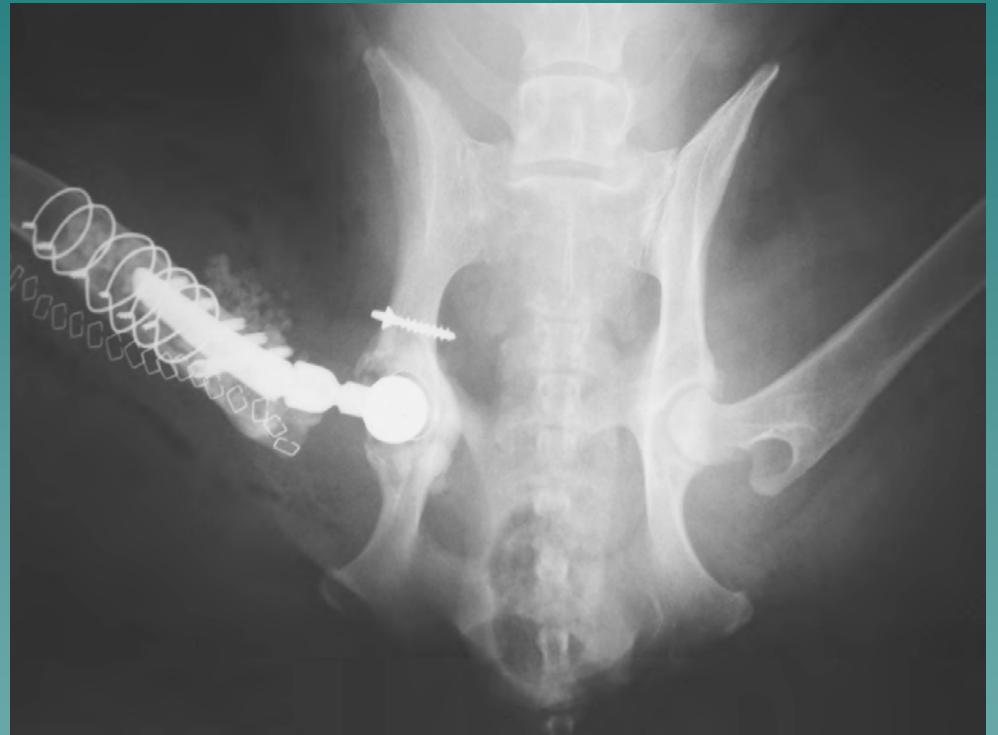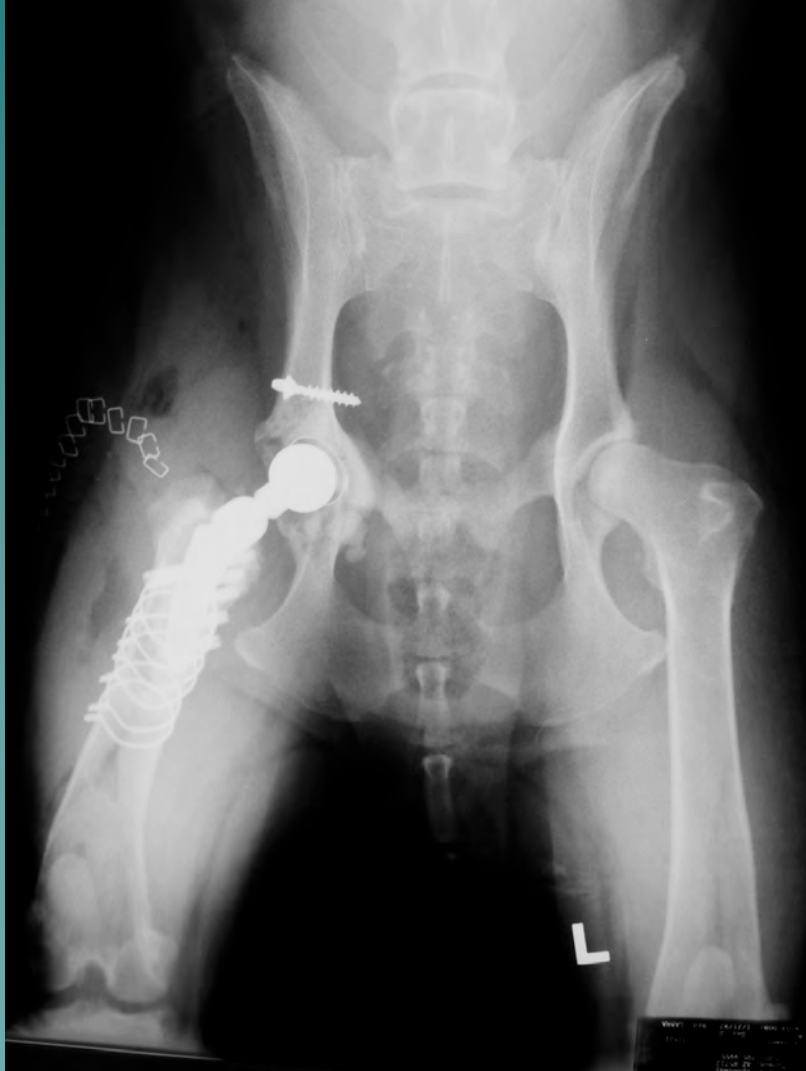# Femoral window replaced after new Kyon stem and beads placed



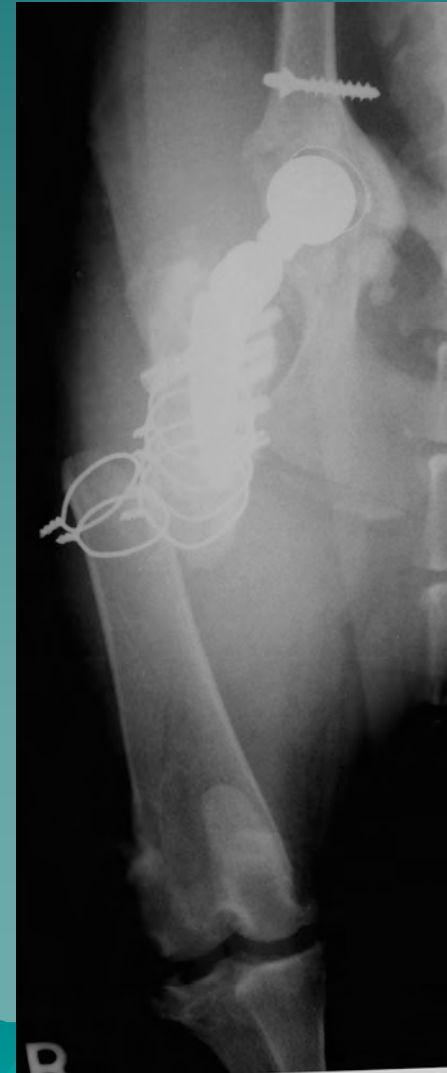
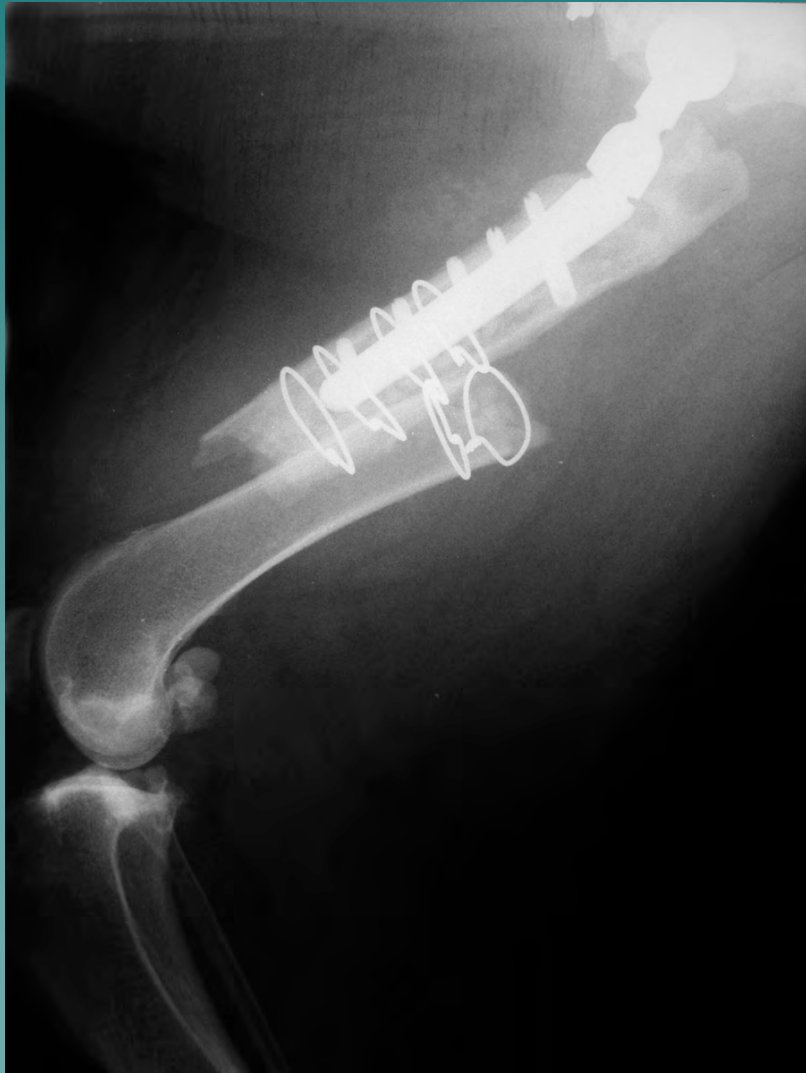
Osteoset beads

Note "Slocum Suture Sling" used to stabilize hip (cup not replaced)

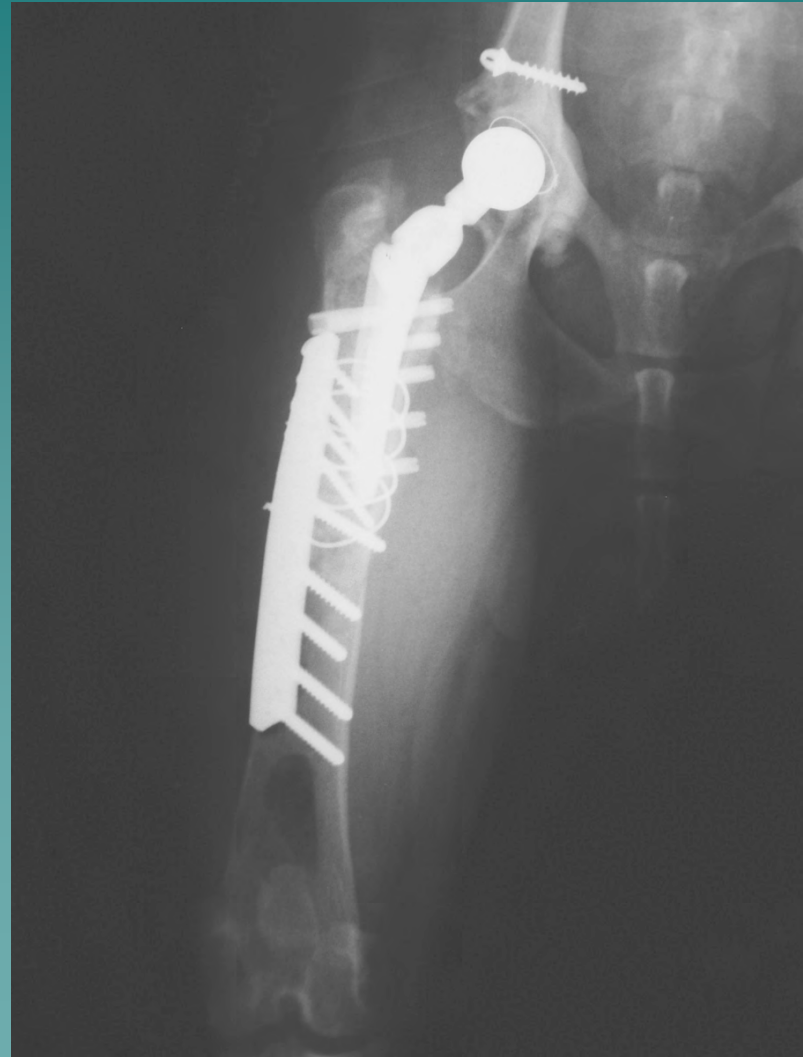
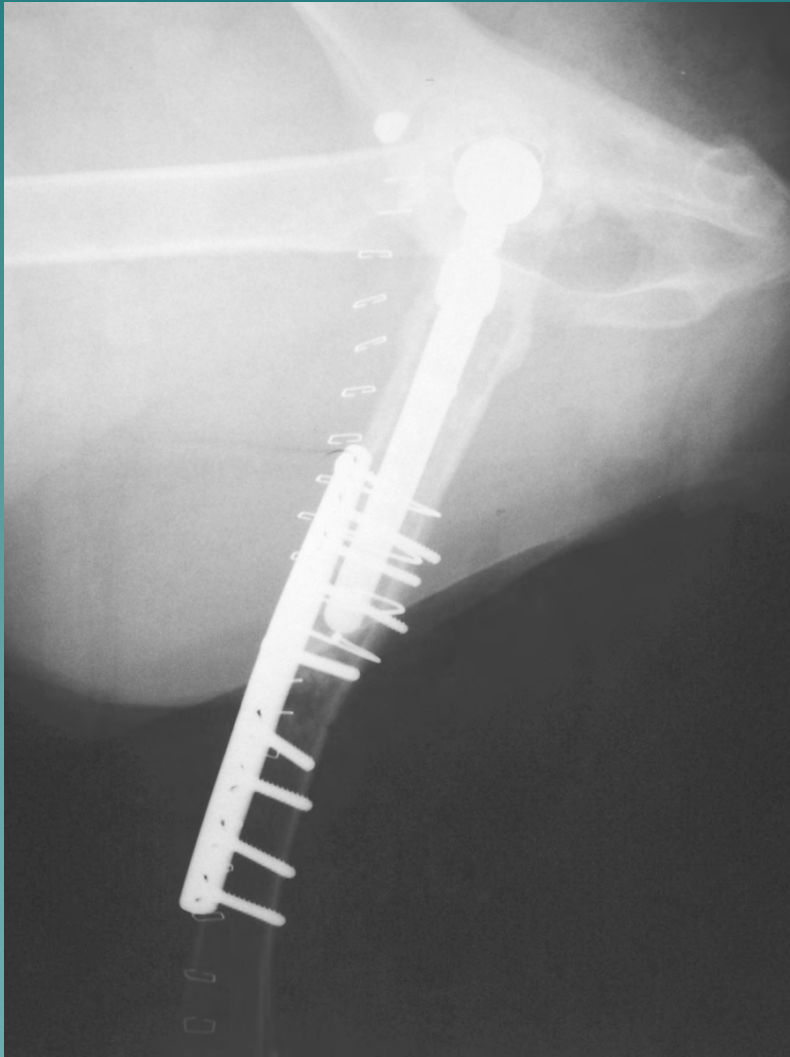
# Postop Radiographs



# Femur fracture 10 days post-op



# Post-op Femur Fracture Repair



# Post-op 2.5 year Hybrid Hip Revision (CFX – Kyon)

